

Promising results wound care  
new rapid capillary action dressing  
case series study

# Promising results in wound care with a new rapid capillary action dressing: a case series study



**Author**  
Alexandra Helena Jacoba Janssen

This case series aimed to describe treatment effects and experiences of patients who switched from negative pressure wound therapy (NPWT) to a rapid capillary action dressing (RCAD; VACUTEX™). Ten consecutive patients who prematurely terminated NPWT were recruited. Mean time to complete wound closure was 87.3 days (SD 38.3). The main reasons for terminating NPWT were maceration of the skin caused by the film and patient discomfort. All patients preferred the RCAD, mainly because of better mobility and no noise, compared to the NPWT device. A RCAD appears to be a promising treatment modality.

**Alexandra Helena Jacoba Janssen** is Nurse Specialist Wound Care, Department of Surgery, Elkerliek Hospital, Helmond, the Netherlands; **Janet Rijploeg** is Wound Care Nurse, Cardio Vascular Centre, Leeuwarden Medical Centre, Leeuwarden, The Netherlands; **Johannes A. Wegdam** is MD, Department of Surgery, Elkerliek Hospital, Helmond, The Netherlands; **Tammo S. de Vries Reilingh** is MD, PhD, Department of Surgery, Elkerliek Hospital, Helmond, The Netherlands; **Hester Vermeulen** is RN, Scientific Institute for Quality of Healthcare (IQ healthcare) Radboud University, Nijmegen, The Netherlands; PhD, HAN University of Applied Science, Faculty of Health and Social Studies, Institute of Nursing, Nijmegen, The Netherlands; **Anne M. Eskes** is RN, Department of Surgery, Amsterdam UMC, University of Amsterdam, Amsterdam, the Netherlands; PhD, Menzies Health Institute Queensland and School of Nursing and Midwifery, Griffith University, Gold Coast, Australia

**S**kin wounds are an important health concern. Based on data from developed countries, it is estimated that approximately 1–2 % of the population will experience a hard-to-heal wound during their lifetime (Gottrup, 2004). These wounds impose a significant and often underappreciated burden to the individual, the healthcare system and society as a whole (Järbrink et al, 2016).

To reduce the burden of wounds and improve quality of life (QoL), adequate wound treatment is necessary. Healthcare professionals continuously seek and demand for innovative and effective wound care products, which can be a challenging task as there is insufficient evidence for many treatment options (Gillespie et al, 2020; Walker et al, 2020).

Negative pressure wound therapy (NPWT) is based on the principle that a negative pressure inside the wound can suction fluids and approximate wound edges (Cozza et al, 2019). This therapy has been used for many years in the treatment of acute and hard-to-heal wounds (Janssen et al, 2020).

Despite the potential benefits of NPWT, there is also some evidence that patients experience harm. It appears that NPWT can have a negative impact on QoL and can lead to serious restrictions in the physical, psychological and social domains of QoL (Janssen et al, 2020). These restrictions even lead to a significant amount of patients requesting a premature termination of NPWT (Janssen et al, 2021).

A treatment modality that may overcome

these negative side-effects is a rapid capillary action dressing (RCAD). VACUTEX™ (Protex, Roeselare, Belgium) consists of three layers, namely two 100% polyester filament outer layers, and a 65% polyester and 35% cotton woven inner layer (Deeth and Pain, 2001). The inner layer, in contact with the wound, is able to lift and transport necrotic and sloughy tissue. The middle layer wicks away the exudate laterally across the fabric and the outer layer draws the exudate from the saturated middle layer (Russell et al, 2001). The soft and conformable RCAD can be cut to size and placed in layers on the surface of the wound (Deeth and Pain, 2001).

The RCAD provides a capillary pressure of –70 to –75 mmHg in the wound (Breitwieser and Viaene, 2021). This may be sufficient, as another study showed that the maximum biological effects of NPWT on the wound are obtained at –80 mmHg (Borgquist et al, 2010; 2011). Therefore, a RCAD could be a valuable alternative to NPWT in terms of better tolerance by the patient and comparable time to achieve complete wound healing.

A quick search in Medline PubMed (up to March 2021) yielded seven studies of a RCAD, six of them published before 2004. Therefore, further investigation and description of this treatment modality is needed.


This case series aimed to describe the treatment effects and the experiences of patients who switched from NPWT to a RCAD. The results of this study can be used to generate hypotheses for future studies.

**Table 1. Baseline characteristics.**

Case	Sex	Age (years)	Wound aetiology/ location	Smoking	BMI	Diabetes	CVA/ TIA	HF	Malignancy	PAD	Interventions
1	M	71	Amputation toes 4 and 5 right foot, wound left open	Unknown	19.9	No	Yes	No	No	Yes	PTA ATA and ATP right foot
2	M	71	Abdominal wound with mesh, fascia closed, wound left open	Stopped	25.7	Yes	No	Yes	Adeno-carcinoma	No	Haemicolectomy right. Laparotomy: seam leakage, abdominal compartment syndrome. Abthera. Close fascia with Biomesh
3	M	76	Postoperative wound infection left knee	No	22.9	No	Yes	Yes	No	Yes	Endovascular treatment of femoral popliteal artery stenosis with stent on the right and PTA of popliteal artery on the right, Infrageneal femoral-popliteal bypass right with silver coated 6 mm prosthesis
4	M	73	Abdominal wound (top and bottom)	Stopped	31.5	No	No	No	No	No	Acute aortic abdominal aneurysm, open procedure. Open abdominal treatment with Abthera. Abthera removed, fascia closed, leaving VAC in subcutis
5	M	70	Forefoot amputation	No	37.4	Yes	No	No	No	Yes	PTA: covered kissing stents AIC on both sides. Forefoot amputation right
6	F	77	Amputation hallux right	No	25.1	Yes	No	No	No	No	Amputation TMT 1 right, approximating closed. Open original amputation wound and shorten MT1. Apply VAC.
7	M	80	Infection vascular prosthesis groin	Stopped	22.9	No	No	No	No	Yes	Sartorius plastic left groin + VAC
8	M	73	Infection vascular prosthesis groin	Stopped	23.5	No	No	No	No	Yes	Bifurcation prosthesis. Removal of left groin seam aneurysm by Gelsoft rifampicin-soaked bifurcation prosthesis. Drainage abscess, infection groin.
9	M	94	Pressure ulcer heel	No	27.8	Yes	Yes	Yes	No	Yes	Wound debridement left heel
10	M	78	Partial amputation toes 2, 3, 4 and 5 right foot	No	33.1	Yes	No	No	No	Yes	PTA popliteal artery, peroneal artery and ATP right. Partial amputation TMT 2 to 5 right

AIC = common iliac artery; ATA = anterior tibial artery; ATP = posterior tibial artery; CVA = cerebrovascular accident; HF = heart failure; PAD: peripheral arterial disease; PTA = percutaneous transluminal angioplasty; TIA = transient ischaemic attack; TMT = transmetatarsal; VAC = vacuum-assisted closure

**Figure 1. Schematic representation of application of the RCAD.**



### Materials and methods

This study is reported according to applicable criteria of the Case Report Guidelines (Riley et al, 2017). The Medical Research Involving Human Subjects Act (does not apply to our research project because there is no infringement of the physical and/or psychological integrity of the patients (Central Committee on Research Involving Human Subjects, 2018).

This case series study prospectively recruited 10 consecutive patients treated in a teaching hospital in the Netherlands between June 2019 and October 2019. Patients were eligible if they prematurely terminated NPWT, either requested themselves or by the wound care specialist. They provided written and verbal informed consent regarding participating in this study and taking pictures of the wound.

Data were collected and noted in the patient chart over the wound healing. When NPWT was terminated, treatment was continued with the RCAD (VACUTEX). In all cases, the RCAD was used in the same way. Depending on the depth of the wound, multiple layers of the RCAD

Table 2. Results.

Case	Wound dimensions at start (length × width × depth, cm)	Duration NPWT (days)	Reason for terminating NPWT	Duration RCAD (days)	Wound dimensions at end	Reason for terminating the RCAD	Duration alternative therapy until wound closure
1	12 × 8 × 3	4 days	Maceration	78 days	3 × 1.5	Wound at skin level, only protection needed	28 days
2	6 × 5 × 1	33 days	Maceration, no progression	78 days	3 × 3	Wound at skin level, hypergranulation, much exudate	Still open
3	13 × 3.5 × 2.5 undermining 6	5 days	Many blood clots	47 days	Closed		
4	Wound 1: 16 × 5 × 4 Wound 2: 8 × 4 × 7	9 days 23 days	1: Wound at skin level 2: Discomfort	17 days 44 days	Both closed		
5	10 × 3 × 2	9 days	Maceration	70 days	6 × 1.5	Hypergranulation	14
6	5 × 2 × 2.5	10 days	Maceration, hypergranulation	43 days	2.8 × 0.5 × 0.2	Wound at skin level and too narrow for capillary bandage	Lost to follow-up
7	6 × 2 × 1	17 days	Maceration, leakage	31 days	0.5 × 1.5	Inexperience with the capillary bandage, relieve of seroma, hypergranulation	Died
8	8 × 2.2 × 1	58 days	Discomfort, maceration, leakage	22 days	3.5 × 1 × 0.5	Bottom part of the wound was closed	22 days
9	6 × 5 × 0.7	14 days	Discomfort, maceration	115 days	Closed		
10	10.5 × 3 × 3	49 days	Maceration	85 days	Closed		

were applied up to skin level. One slightly larger layer was put on top of the other dressings, with an overlay of ± 1 cm on the surrounding skin [Figure 1]. The dressings were cut 2 mm smaller than the wound, enabling approximation of the wound edges. The RCAD was covered with an absorbent dressing. The RCAD was changed twice a week and the absorbent dressing every day.

The reasons for premature termination of NPWT were noted. Wound dimensions at the start of NPWT therapy, length of the treatment with NPWT and with RCAD, and time to complete wound closure were recorded. After hospital discharge, all patients were admitted to the rehabilitation centre, located near the hospital. Patients were followed up by the hospital's wound care consultant until complete wound closure was obtained. Wound closure was defined as 100% epithelialisation of the wound surface with no discernible exudate and without drainage or dressing (Gould and Li, 2019). Patients' experiences with NPWT and RCAD were noted.

## Results

Ten patients were included in this study. None of the patients declined participation. Nine men and one woman were included, with 11 wounds of different aetiologies. All wounds were

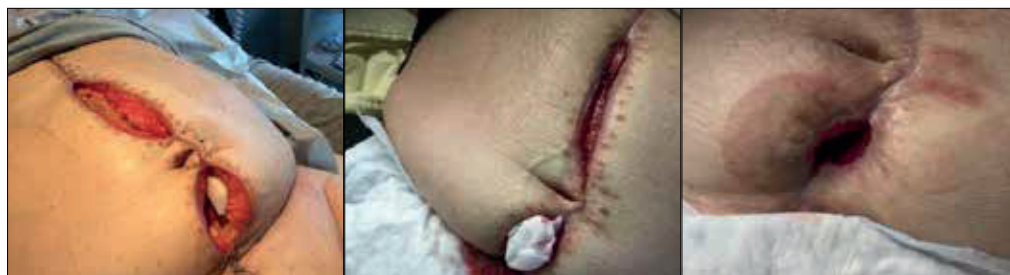postoperative: four toe/partial foot amputations, three abdominal wounds, one lower leg wound, two groin wounds. One wound was a heel pressure ulcer (after surgical debridement). The baseline characteristics are described in Table 1. One patient was lost to follow-up, one patient died and one patient still had an open wound at time of writing. The other eight wounds were healed.

## Treatment effects

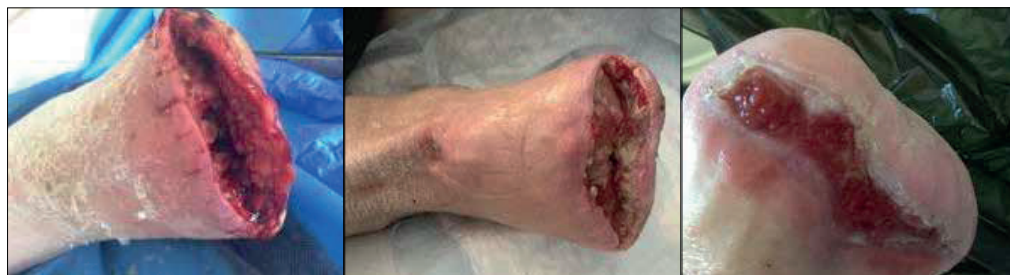All patients received NPWT according to the local protocol, with the aim to continue this therapy until granulation tissue reached the skin level. The Vacuum Assisted Closure® (V.A.C.®) Therapy device (Kinetic Concepts Inc, San Antonio, TX, US) was used in all 10 patients. Dressings were changed twice a week. Continuous negative pressure levels of –125 mmHg were used in all patients (Acelity, 2015). Median duration of NPWT was 14 days (IQR 24). The NPWT was discontinued, either by the patients themselves or the wound care specialist. The reasons for premature termination of NPWT are described in Table 2.

Four cases are shown in Figures 2–5 and the other case images can be found in Appendix 1, which is available online to accompany this article.

**Figure 2.** Case 4 was a 73-year-old man with two abdominal wounds. Left to right: At start of NPWT; Start of RCAD on upper wound; Upper wound closed.



**Figure 3.** Case 5 was a 70-year-old man with right forefoot amputation. Left to right: At start of NPWT; Start of RCAD; Superficial wound, hypergranulation, so the RCAD was stopped and Terracortril started.



All patients continued their wound treatment with the RCAD (VACUTEX) after discontinuation of NPWT. Four patients (with five wounds) continued the RCAD until complete wound closure, and six patients switched wound therapy when the granulation tissue reached skin level. Mean duration of treatment with the RCAD was 57.3 days (SD 30.3). In case of exposed tendon it was overgrown with tissue during treatment with the RCAD. In two cases, the tendon was kept moist with a hydrogel beneath the RCAD. During treatment with the RCAD, three patients (cases 2, 5 and 7) developed hypergranulation.

In all patients, the dressing was soaked with tap water before removing. None of the patients indicated pain at dressing changes. No residual particles of the dressing were seen. Although all wounds were hard to heal, all but one showed progression in wound healing. Mean time to complete wound closure was 87.3 days (SD 38.3).

In seven cases (1, 2, 5, 6, 7, 9 and 10), despite correct application of the NPWT, the pump could not handle the amount of exudate, which resulted in maceration of the skin, alarms or the film to coming off. This resulted in premature termination of this therapy. No skin maceration was seen during treatment with the RCAD.

***“Everything was soaking wet, and that the pump was roaring and my clothes and chairs got dirty ... so I could not go anywhere, horrible.” – Patient***

In case 3, there were so many blood clots at the first bandage change for NPWT that the

wound care specialist decided to terminate the therapy [Figure 5].

#### **Experiences of patients: NPWT versus RCAD**

Cases 4, 8 and 9 experienced a high level of discomfort during NPWT and indicated the wish to terminate this therapy. All three patients mentioned restrictions in mobility. Because of the pump and the tube, they needed help with transfers and walking. They were annoyed that they had to be constantly aware that they were attached to a pump. When treatment was switched to the RCAD, all three patients indicated they felt more free and independent.

As well as restrictions in movement, cases 8 and 9 indicated the dressing changes during NPWT were very painful. With the RCAD, they experienced no pain. With wounds located in the groin and at the heel, they experienced more comfort from the dressing itself during treatment with the RCAD.

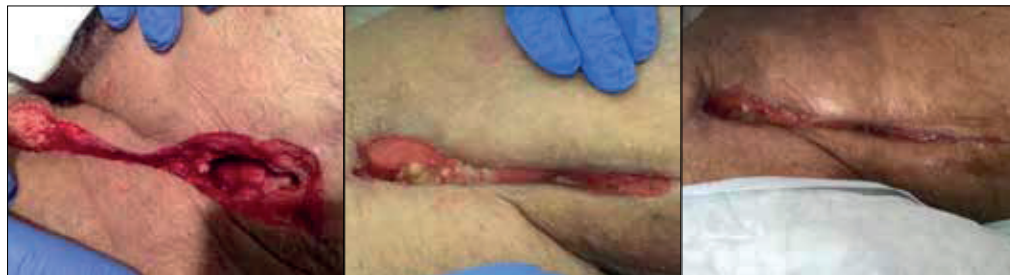All 10 patients mentioned the reduced freedom of movement, the noises of the pump and the burden of carrying it with them as very uncomfortable and indicated a relief to be able to stop NPWT.

***“Luckily I got rid of that hum and squeak.” — Patient***

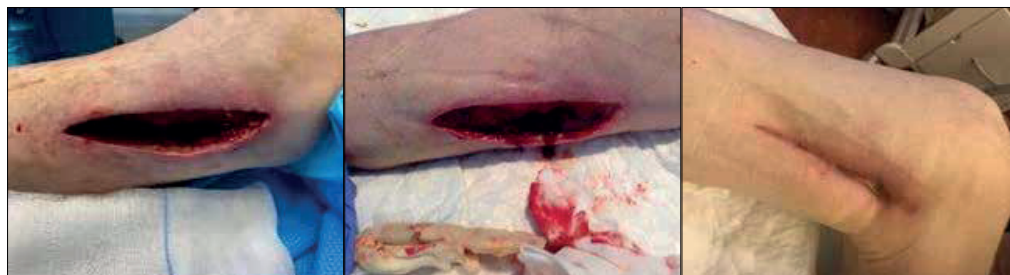#### **Discussion**

This case series indicates that the RCAD (VACUTEX) is a promising treatment modality if NPWT does not suffice. The patients in this case series were treated with both treatment modalities and preferred the RCAD, mainly

**Figure 4.** Case 8 was a 73-year-old man with an infected vascular groin prosthesis. Left to right: At start of NPWT; Start of RCAD; Wound nearly closed.



**Figure 5.** Case 3 was a 76-year-old man with postoperative wound infection in his left knee. Left to right: At start of NPWT; Blood clots led to termination of NPWT and start of the RCAD; Wound nearly closed, unfortunately leg was later amputated after bypass infection.



because of the freedom of movement and the absence of pump noises.

Although strong evidence of the effectiveness of a RCAD is still lacking, this case series indicates that a RCAD might be an interesting treatment modality to consider when the results of NPWT are insufficient and/or when patients indicate they wish to stop NPWT.

When making a clinical decision on treatment using an evidence-based practice approach, the best evidence from well-designed studies, clinicians' expertise and patients' preferences and values should be integrated (Melnik et al, 2012). Because evidence on the effectiveness of a RCAD is still lacking, patients' preferences become even more important and should be considered.

The conjoint analysis of Vermeulen et al (2007) showed that little pain during dressing changes, short duration of hospitalisation, and quick wound healing were the most preferred attributes of an "ideal" wound dressing for local wound care, in the opinion of doctors, nurses and patients. Participants in this case series clearly stated their preference for the RCAD over NPWT. Most wounds showed marked wound healing with the RCAD without the inconveniences of NPWT.

It was remarkable that three out of 11 wounds showed hypergranulating tissue during the use of the RCAD. Hypergranulation can be defined as excess of granulation tissue that fills the wound bed to a greater extent than what is required and goes beyond the height of the surface of the wound, resulting in a raised tissue mass (Jaeger et al, 2016). To

date, there is no consensus on how to manage these wounds (McGrath, 2011). One of the treatment options is "wait and see", because hypergranulation is often transient and will resolve itself (Dunford, 1999; Vuolo, 2010). In this case series, according to standard protocol, it was decided to stop the RCAD and start with Terracortril (containing oxytetracycline and hydrocortisone). In all three patients, the hypergranulation disappeared. We do not know whether this would have happened if we had continued the treatment with the RCAD. In further studies with a RCAD, hypergranulation as secondary outcome should be considered.

In this case series, it should be taken into account that there might be a carry-over effect. All the included patients in this case series were first treated with NPWT, which may have given the wound a start in healing. Perhaps the RCAD should be used in a step-down model: start with NPWT and when the wound shows signs of healing, switch to the RCAD. However, experiences in our wound centres show also promising results of the RCAD as a replacement for NPWT.

Russell et al (2001) studied the differences between a RCAD and standard protocol in time to a clean wound bed. The preliminary results of that small multicentre randomised trial (35 participants) suggested that the RCAD may be a useful new treatment for dealing with sloughy, devitalised and exuding wounds. However, the authors did not study time to complete wound healing and did not compare the RCAD with NPWT. Also patients' experiences with the RCAD compared to standard protocol were not considered.

Further experimental research with a RCAD as an alternative to NPWT is recommended.

## Conclusion

This is, to our knowledge, the first case series utilising a RCAD in patients with hard-to-heal wounds. Although case series do not provide robust evidence in terms of efficacy of one treatment above another, they are valuable because they illustrate cases in true clinical practice and have high external validity (Coroneos et al, 2011). The promising results of this case series indicate the value of conducting a RCT comparing the efficiency of a RCAD with NPWT. In this RCT, one could hypothesise that the RCAD results in less skin problems, higher patient satisfaction and possibly faster wound healing rates.

WINT

## References

- Acelity (2015) V.A.C.® Therapy Clinical guidelines: a reference source for clinicians. Available from: <https://www.acelity.com/-/media/Project/Acelity/Acelity-Base-Sites/shared/PDF/2-b-128h-vac-clinical-guidelines-web.pdf> (accessed 06.08.2021)
- Borgquist O, Ingemansson R, Malmjö M (2010) Wound edge microvascular blood flow during negative-pressure wound therapy: examining the effects of pressures from -10 to -175 mmHg. *Plast Reconstr Surg* 125(2): 502-9
- Borgquist O, Ingemansson R, Malmjö M (2011) The influence of low and high pressure levels during negative-pressure wound therapy on wound contraction and fluid evacuation. *Plast Reconstr Surg* 127(2): 551-9
- Breitwieser M, Viaene D (2021) Capillary pressure in wound dressings: an investigation on behalf of Protex Healthcare Ltd. Available at: <https://www.imeter.de/120VACUTEX2020eng> (accessed 06.08.2021)
- Central Committee on Research Involving Human Subjects (2018) Your research: Is it subject to the WMO or not? Available from: <https://english.ccmo.nl/investigators/legal-framework-for-medical-scientific-research/your-research-is-it-subject-to-the-wmo-or-not> (accessed 06.08.2021)
- Coroneos C J, Ignacy TA, Thoma A (2011) Designing and reporting case series in plastic surgery. *Plast Reconstr Surg* 128(4): 361e-8e
- Cozza V, Pascale MM, Pepe G et al (2019) Empirical measurement of pressure in negative pressure wound therapy for infected wounds: how long can it really stay under pressure? *Wound Repair Regen* 27(2): 190-5
- Deeth M, Pain L (2001) VACUTEX: a dressing designed for patients, tailored by nurses. *Br J Nurs* 10(4): 268-71
- Dunford C (1999) Hypergranulation tissue. *J Wound Care* 8(10): 506-7
- Gillespie BM, Walker RM, McInnes E et al (2020) Preoperative and postoperative recommendations to surgical wound care interventions: a systematic meta-review of Cochrane reviews. *Int J Nurs Stud* 102: 103486
- Gottrup F (2004) A specialized wound-healing center concept: importance of a multidisciplinary department structure and surgical treatment facilities in the treatment of chronic wounds. *Am J Surg* 187(5A): 38s-43s
- Gould L, Li WW (2019) Defining complete wound closure: closing the gap in clinical trials and practice. *Wound Repair Regen* 27(3): 201-24
- Jaeger M, Harats M, Kornhaber R et al (2016) Treatment of hypergranulation tissue in burn wounds with topical steroid dressings: a case series. *Int Med Case Rep J* 9: 241-5
- Janssen AH, Wegdam JA, de Vries Reilingh TS et al (2020) Negative pressure wound therapy for patients with hard-to-heal wounds: a systematic review. *J Wound Care* 29(4): 206-12
- Janssen AH, Wegdam JA, de Vries Reilingh TS et al (2021) Which determinants are considered to be important for adherence to negative pressure wound therapy: a multimethods study. *J Tissue Viability* 30(2): 250-5
- Järbrink K, Ni G, Sönnnergren H et al (2016) Prevalence and incidence of chronic wounds and related complications: a protocol for a systematic review. *Syst Rev* 5(1): 152
- McGrath A (2011) Overcoming the challenge of overgranulation. *Wounds UK* 7(1): 42-9
- Melnyk BM, Fineout-Overholt E, Gallagher-Ford L, Kaplan L (2012) The state of evidence-based practice in US nurses: critical implications for nurse leaders and educators. *J Nurs Adm* 42(9): 410-7
- Riley DS, Barber MS, Kienle GS et al (2017) CARE guidelines for case reports: explanation and elaboration document. *J Clin Epidemiol* 89: 218-35
- Russell L, Deeth M, Jones HM, Reynolds T (2001) VACUTEX capillary action dressing: a multicentre, randomized trial. *Br J Nurs* 10(11 Suppl): S66-70
- Vermeulen H, Ubbink DT, de Zwart F et al (2007) Preferences of patients, doctors, and nurses regarding wound dressing characteristics: a conjoint analysis. *Wound Repair Regen* 15(3): 302-7
- Vuolo J (2010) Hypergranulation: exploring possible management options. *Br J Nurs* 19 (Suppl 2): S4-8
- Walker RM, Gillespie BM, McInnes E et al (2020) Prevention and treatment of pressure injuries: a meta-synthesis of Cochrane reviews. *J Tissue Viability* 29(4): 227-43

