

Treatment With Oxygen-Enriched Olive Oil Improves Healing Parameters Following Augmentation-Mastopexy

Adriano Santorelli, MD^o; Marco Bernini, MD; Lorenzo Orzalesi, MD; Stefano Avvedimento, MD^o; Paolo Palumbo, MD; Ashutosh Kothari, MD; Alfonso Fausto, MD^o; Cesare Magalotti, MD; Giuseppina Buzzi, MD; Sara Sandroni, RN; and Claudio Calabrese, MD

Aesthetic Surgery Journal Open Forum 2021, 1–10

© 2021 The Aesthetic Society.

This is an Open Access article distributed under the terms of the Creative Commons Attribution-NonCommercial License (<http://creativecommons.org/licenses/by-nc/4.0/>), which permits non-commercial re-use, distribution, and reproduction in any medium, provided the original work is properly cited. For commercial re-use, please contact journals.permissions@oup.com

DOI: 10.1093/asjof/ojab016

www.asjopenforum.com

OXFORD
UNIVERSITY PRESS

Abstract

Background: Breast augmentation-mastopexy can yield an aesthetically attractive breast, but the 1-stage procedure is prone to unsatisfactory outcomes, including poor wound healing.

Objectives: The authors evaluated whether postsurgical application of a polyurethane bra cup coated with oxygen-enriched olive oil (NovoX Cup; Moss SpA, Lesa, Novara, Italy) would decrease pain associated with augmentation-mastopexy and improve the quality of the surgical scar.

Methods: This retrospective study was conducted at a single center from January 2016 to June 2019. All patients underwent 1-stage augmentation-mastopexy with the inverted T incision. For 2 weeks postsurgically, wounds were dressed either with the oxygen-enriched olive oil bra or with Fitostimoline (Farmaceutici Damor SpA, Naples, Italy). Patients indicated their pain intensity on postoperative days 2, 3, and 10, and patients and independent observers scored scar quality on the Patient and Observer Scar Assessment Scale (POSAS) 6 and 12 months after the procedure.

Results: A total of 240 women (120 per study arm) completed the study. All the patients had satisfactory aesthetic results, and there were no tolerability concerns with either postoperative dressing. Compared with patients in the Fitostimoline group, patients who received the oxygen-enriched olive oil bra cup had significantly lower pain levels, and their surgical scars were given better scores on the POSAS.

Conclusions: The results suggest that maintenance of the surgical wound in a film of oxygen-enriched olive oil for 2 weeks is a safe, effective modality for suppressing pain and promoting healing following augmentation-mastopexy.

Level of Evidence: 2

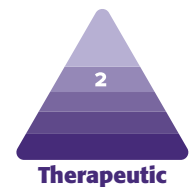
Editorial Decision date: March 18, 2021; online publish-ahead-of-print May 4, 2021.

Dr Santorelli is a plastic surgeon in private practice in Naples, Italy. Drs Bernini and Orzalesi are breast surgeons, Breast Unit, Oncology Department, Careggi University Hospital, Florence, Italy. Dr Avvedimento is a plastic surgeon, Plastic Surgery Unit, Villa dei Fiori, Naples, Italy. Dr Palumbo is a specialist in vascular surgery, Prato, Italy. Dr Kothari is chief of the Breast Surgery Unit, Guy's Hospital, Guy's and St. Thomas' NHS Foundation Trust, London, UK. Dr Fausto is a radiologist, Department of Diagnostic Imaging, University Hospital of Siena, Azienda Ospedaliera Universitaria Senese, Siena, Italy. Dr Magalotti is a breast surgeon, Breast Unit, Ospedali Marche Nord, Pesaro and Urbino, Italy. Dr Buzzi is a breast surgeon in

private practice in Milan, Italy. Ms Sandroni is senior nurse manager, Network Wound Care Azienda USL Toscana Sud Est, Arezzo, Italy. Dr Calabrese is chief of the San Rossore Breast Unit, Casa di Cura San Rossore, Pisa, Italy.

Corresponding Author:

Dr Adriano Santorelli, Department of Plastic Surgery, Academy of Aesthetic Sciences, via Raffaele Morghen 88, 80129, Naples, Italy. E-mail: dott.adrianosantorelli@gmail.com



Single-stage breast augmentation-mastopexy is a challenging procedure that requires extensive surgical skill and experience.^{1,3} The combined technique involves opposing objectives: tightening, lifting, and resecting breast tissue while also adding volume and projection, which stretches the skin envelope.^{1,4} Despite the drawbacks, 1-stage augmentation-mastopexy is relatively popular⁵ because both lower-pole tissue resection and upper-pole augmentation are necessary to achieve the appearance of a lifted, youthful breast.^{4,6} Undergoing separate mastopexy and implantation operations has disadvantages of compounded cost, anesthesia needs, and recovery time and usually involves a period of unsatisfactory appearance between operations.⁴

Augmentation-mastopexy is associated with poor aesthetic results and complications; among these, deficient healing of the surgical wound is of particular concern.^{1,3} In a series of 55 women who received this procedure, 6 (10.9%) experienced dehiscence that healed by secondary intention, and 1 (1.8%) had hypertrophic scarring.² Findings of a review of 186 primary cases of augmentation-mastopexy were that revisional surgery was needed in 16.7% of cases, with poor scarring necessitating revision in 2.2% of the patients (4 of 186).⁵ Similar results have been found in larger patient populations. In a meta-analysis of 4856 cases of simultaneous augmentation-mastopexy, poor scarring was the second most common individual complication, affecting 3.7% of the patients.³ Findings of a single-center retrospective review of 615 consecutive 1-stage augmentation-mastopexy cases indicated that the 2 most common complications were poor scarring (5.7%) and wound-healing problems (2.9%), with 4.7% of the patients choosing to undergo revisional surgery because of unacceptable scarring.⁷ Modalities that support and promote wound healing could help avoid these unfavorable outcomes and improve rates of patient satisfaction.

Numerous lines of evidence show that wound healing is impaired in hypoxic conditions, and oxygen is required for nearly every cellular processes involved in healing, including proliferation, bacterial defense, angiogenesis, and collagen synthesis.^{8,9} Upon cutaneous injury and inflammation, reactive oxygen species (ROS) are generated at the wound site by neutrophils and activated macrophages.¹⁰ In uncomplicated wound healing, ROS function as secondary messengers to immunocytes and nonlymphoid cells involved in tissue repair, recruiting immune factors and encouraging angiogenesis at the wound site.¹¹ When applied exogenously to a wound, ROS exhibit antimicrobial activity and promote tissue oxygenation, local immune stimulation, and wound closure.^{11,12} ROS-related damage to host cells is circumvented to some extent by free-radical sensing and consequent upregulation of cytoprotective genes.¹⁰

Olive oil comprises a mixture of glycerides, predominantly oleic acid, that provides a stable matrix for ROS



Figure 1. The NovoX Cup (Moss SpA, Lesa, Novara, Italy) is a bra insert that is applied postsurgically to promote wound healing. The cup has an inner coating of oxygen-enriched olive oil and is available in 4 sizes.

when reacted with ozone.¹³⁻¹⁸ Application of an oxygen-enriched oleic matrix to the skin has been found to lower the rate of secondary surgical infections¹⁴ and to promote healing of deep and narrow wounds, including those caused by surgical procedures.¹⁸ Herein, we present our findings with the NovoX Cup (Moss SpA, Lesa, Novara, Italy), a single-use polyurethane bra insert with an inner coating of oxygen-enriched olive oil that is indicated for the treatment of surgical wounds of the breast, including those associated with mastectomy, breast augmentation, or breast reduction as well as hypertrophic scarring, superficial burns, and pressure ulcers. NovoX Cups are supplied as small, medium, large, or extra-large sizes (Figure 1) and are applied to the breast in the early postoperative period to ensure continuous contact of the surgical wound with oxygen-enriched olive oil. The device contains no other antimicrobials or chemical additives.

METHODS

We conducted a retrospective study of a consecutive series of patients who underwent 1-stage augmentation-mastopexy at our clinic between January 2016 and June 2019. We used data from a specific “augmentation-mastopexy” database that was created and prospectively maintained by the first author (A.S.). All work was conducted in accordance with guidelines set forth in the Declaration of Helsinki, and informed consent was obtained from all patients before enrollment. Patients who presented for treatment owing to weight loss or previous pregnancy were included. Exclusion criteria were a history of neoplastic breast disease, post-oncologic breast reconstruction, pathologic scarring,

diabetes mellitus, autoimmune disease, connective tissue disease, or mammary pseudoptosis (according to the Regnault classification¹⁹); smoking more than 20 cigarettes per day; or a body mass index (BMI) >30 kg/m². Former smokers who had ceased smoking >14 days presurgically were included in the study.

On the basis of available dressing materials, patients were allocated to receive either of 2 postsurgical dressings: the NovoX Cup containing oxygen-enriched olive oil (treatment group) that we introduced in our practice from January 2016 or Fitostimoline-soaked gauze (control group) (Farmaceutici Damor SpA, Naples, Italy). Fitostimoline is formulated with the aqueous extract of *Triticum vulgare*; it is broadly used in postoperative scar treatment to promote a moist environment and pain reduction,²⁰ and it has been widely used in our practice as a standard postoperative dressing.

All procedures were performed by the same surgeon (A.S.). Patients received antibiotic therapy (cephalosporin and gentamicin) intraoperatively and underwent 1-stage augmentation-mastopexy by means of an inverted T (or Wise) technique, as described previously.²¹ The resection pattern was chosen because it enables the nipple-areola complex (NAC) to be raised while tightening the lower pole.² After careful disinfection with 10% povidone-iodine and washing with saline solution, all patients received bilateral augmentation by means of a microtextured prosthesis placed in a dual plane (superiorly submuscular and inferiorly subglandular). Implant volumes ranged from 295 to 415 mL and were chosen with regard to the extent of ptosis, the patient's physical characteristics, and the desired postoperative breast size. Absorbable intradermal sutures were placed at the level of the NAC and the inverted T. To minimize infection-related complications, no patient received suction drains.^{22,23}

Immediately postoperatively, the NovoX Cup or Fitostimoline dressing was applied. On the second postoperative day, the dressings were changed, and the surgical area was evaluated by the surgeon for vascularization of the flaps and NAC as well as for ischemia of the skin microcirculation or blood loss. Dressings were changed by the patient once or twice during the first 10 days. On postoperative day 11, dressings were again changed by medical personnel, and the wounds were observed. The dressings were definitely removed on day 14 if no complications were observed.

Patients were asked to rate their pain on a numeric pain intensity scale from 0 (no pain) to 10 (worst pain possible) on postsurgical days 2, 3, and 10. Six and 12 months postoperatively, patients and observers rated scar quality on the Patient and Observer Scar Assessment Scale (POSAS).²⁴ Observers were medical professionals

Table 1. Questions Posed to Observer and Patient in the POSAS²⁴

Observer	Patient
Vascularization	Is the scar painful?
Pigmentation Hypo, Mix, Hyper	Is the scar itching?
	Is the color of the scar different?
Thickness	Is the scar more stiff?
Relief	Is the thickness of the scar different?
Pliability	Is the scar irregular?
Total Observer Score: 0-50	Total Patient Score: 0-60

POSAS, Patient and Observer Scar Assessment Scale.

who had not performed any of the study operations and who were blinded to the surgical dressing applied. The POSAS is a reliable instrument that accounts for the opinions of the observer and the patient on separate scales and addresses numerous aspects of scar quality.²⁴ The observer and patient rate the scar from 1 ("normal skin" or "no complaints") to 10 ("worst scar imaginable" or "very different") according to the categories presented in Table 1. The resulting composite scores range from 5 to 50 for the observer and from 6 to 60 for the patient.²⁴ Patients also were asked to indicate their level of satisfaction with the surgical results 1 year postoperatively.

MATLAB R2018a (MathWorks, Inc., Natick, MA) software was utilized for statistical analysis. To ascertain differences in pain intensity and scar scores by surgical dressing applied, the Wilcoxon rank sum test and the Kruskal-Wallis chi-square test with Bonferroni correction were performed. Statistical significance was defined as $P < 0.05$.

RESULTS

Data from 249 patients (oxygen-enriched olive oil bra, $n = 125$; Fitostimoline, $n = 124$) were collected. Nine patients (5 in the oxygen-enriched olive oil bra group and 4 in the Fitostimoline group) had incomplete data and were excluded from the analysis. The remaining 240 patients (120 per group) completed the study and were included in the analyses; there were no other patients lost to follow-up. Mean patient age was 49.2 years (range: 22-66 years); BMI was 21.3 kg/m² (range: 15.6-28.4 kg/m²).

Patient age and BMI were similar in the groups. In the oxygen-enriched olive oil bra group, the mean age was 49.8 years (range: 24-63 years), and mean BMI was 21.1 kg/m² (range: 15.7-27.1 kg/m²); in the Fitostimoline group, the mean age was 48.7 years (range: 22-66 years), and mean

Table 2. One-Month Postoperative Complications

Complication	NovoX Cup	Fitostimoline
Wound dehiscence	2	10
Hypertrophic scarring	0	0
Keloid	0	0
Infection	1	1
Reoperation (not scar related)	1	2
Scar diastasis	1	6

BMI was 21.5 kg/m² (range: 15.6-28.4 kg/m²). Patients in both groups expressed their satisfaction with the aesthetic results, and no patient had safety or tolerability concerns related to the wound dressings. Surgical complications that occurred by 1 month postoperatively are presented in [Table 2](#).

Pain Intensity

Pain intensity scores are shown in [Figure 2](#) as box-and-whisker plots, where the heavy lines depict medians, the box edges indicate first and third quartiles, the whiskers depict the range (excluding outliers), and the open circles represent outliers. Pain intensity data also are shown in terms of pseudomedians and confidence intervals (CIs) in [Supplemental Figure 1](#), available as [Supplemental Material](#) at www.aestheticsurgeryjournal.com. The pseudomedian is a positional index that is preferred to the crude median in distributions that are nonparametric, asymmetric, or heterogeneous in variance.²⁵

On postoperative day 2, patients indicated similar levels of pain intensity in both study arms. However, by day 3, those who received the oxygen-enriched olive oil bra had significantly less pain than did those in the Fitostimoline arm (median pain intensity: 3.5 vs 5). The change in median pain from day 2 to 3 was -41.7% in the oxygen-enriched olive oil bra group vs -9.1% in the Fitostimoline group. On day 10, 79% of the patients who received the oxygen-enriched olive oil bra indicated that they had no pain, and the other 21% of patients in this group indicate a pain score of 1; the oxygen-enriched olive oil bra group again had significantly lower pain scores than did the Fitostimoline group (0 vs 3). In the Fitostimoline group on day 10, only 5% of patients reported having no pain, and 14% rated their pain as 1.

Scar Quality

Six months postsurgically, patients whose wounds were dressed with the oxygen-enriched olive oil bra had a

patient-reported pseudomedian scar score of 25 on the POSAS (95% CI: 23-26.5), whereas those who received Fitostimoline had a worse scar score (pseudomedian, 38; 95% CI: 40.5-35) ([Figure 3](#)). The between-group difference at this time point was statistically significant ($P < 0.0001$). By 12 months postoperatively, patients in both groups indicated improved scar quality from the 6-month values (both, $P < 0.0001$), with the oxygen-enriched olive oil bra group still significantly better than the Fitostimoline group (oxygen-enriched olive oil bra pseudomedian: 6 [95% CI: 5.5-6]; Fitostimoline pseudomedian: 9.5 [95% CI: 9-10]) ($P < 0.0001$).

Independent observers blinded to the treatment group also indicated significantly better scar quality in the oxygen-enriched olive oil bra group than in the Fitostimoline group 6 months postoperatively (pseudomedian: 20 [95% CI: 18-20.5] vs 23 [21-24.5]) and 12 months postoperatively (pseudomedian: 6 [95% CI: 5.5-6] vs 9 [8.5-9.5]) (both, $P < 0.0001$) ([Figure 4](#)). Within each group, the observers rated the scars significantly improved at the 12-month visit compared with 6 months (both, $P < 0.0001$). Five-number summaries of POSAS data are provided in [Supplemental Figure 2](#), and a tabulated comparison of median and pseudomedian data for POSAS scores in this study is provided in [Supplemental Tables 1 and 2](#); available as [Supplemental Material](#) at www.aestheticsurgeryjournal.com.

Representative images of patients who received the oxygen-enriched olive oil bra or Fitostimoline dressings are depicted in [Figures 5 and 6](#), respectively. In general, the surgical scars in patients who received the oxygen-enriched olive oil bra were flat, symmetric, and inconspicuous. In contrast, the patients who received Fitostimoline gauze tended to have tissue constriction at the inverted T junction and irregularities of the periareolar scar.

DISCUSSION

Single-stage augmentation-mastopexy is popular because it enables surgeons to restore all aspects of a youthful breast. Breast implantation alone cannot correct skin laxity, and mastopexy alone cannot create volume.⁴ The primary goals of augmentation-mastopexy are harmonious shape and the smallest possible scar.²⁶ However, even in experienced hands, augmentation-mastopexy poses relatively high risks of secondary infection, wound dehiscence, and poor scar quality—especially at the inferior junction of the inverted T.²

The oxygen-enriched olive oil bra shows promise as an innovative wound-healing modality for surgical procedures of the breast. Oxygen-enriched oil already is recognized in periodontic and endodontic disciplines as

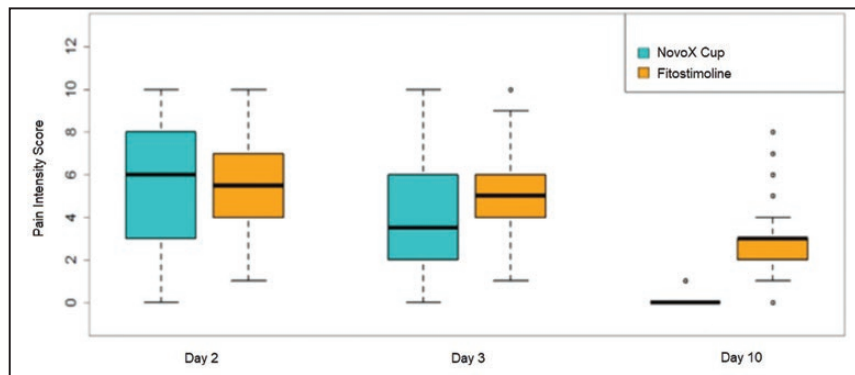


Figure 2. Pain intensity in the early postoperative period. Patients were blinded to the type of surgical dressing received.

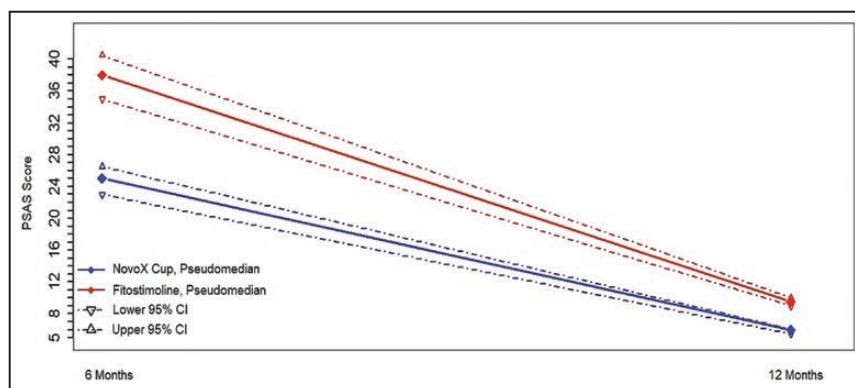


Figure 3. Six and 12 months postoperatively, patients in the study indicated their assessment of the surgical scar by means of the PSAS (ie, the patient component of the Patient and Observer Scar Assessment Scale [POSAS]). Patients were blinded to the type of surgical dressing applied. CI, confidence interval.

an adjuvant to suppress bacterial colonization and as a debriding agent that facilitates a microenvironment capable of stimulating angiogenesis.^{15,27} Twice-daily application of oxygen-enriched olive oil to oral lesions for up to 6 months yielded improvement in all 50 evaluated patients, with no toxicity or side effects.²⁸ Additionally, patients randomly allocated to receive oxygen-enriched oil had better oral epithelial healing than did patients who received control oil.^{29,30}

In several small studies, the application of oxygen-enriched oil has shown efficacy in healing refractory cutaneous lesions. In 2 patients, rinsing with oxygenated water and application of oxygen-enriched oil achieved complete or near-complete healing of methicillin-resistant *Staphylococcus aureus* skin ulceration and decreased pain and swelling.³¹ In a series of 20 patients who had intractable fistulae or wounds following surgery, oxygen-enriched olive oil promoted pus discharge and the formation of granulation tissue without adverse effects, resulting in fully healed wounds in 19 of the patients (95%).³² Injection of oxygenated olive oil for an average of 3 months into

persistent perianal fistulae resulted in healing in 17 of the 26 patients (65.4%).¹⁷ In a randomized clinical trial, investigators demonstrated that oxygen-enriched olive oil applied to leishmaniasis ulcers, in combination with glucantime, resulted in more rapid and complete healing of lesions and improved scar appearance, vs glucantime alone.¹⁴ Finally, in patients with deep and narrow wounds (mostly postsurgical dehiscences), topical application of oxygen-enriched olive oil combined with secondary dressing for 2 to 4 weeks was associated with wound healing and pain relief without tolerability issues or wound recurrence during follow-up.¹⁸

We employed augmentation-mastopexy with an inverted T incision, which results in a long inframammary scar that is associated with potentially high rates of patient dissatisfaction, ranging from 11% to 71%.⁶ The inverted T maneuver is particularly prone to wound-healing complications because the new implant compresses the incision site.⁴ However, in patients with severe ptosis and vertical skin excess, only the inverted T incision is indicated to accomplish adequate vertical displacement of the breast tissue.⁴

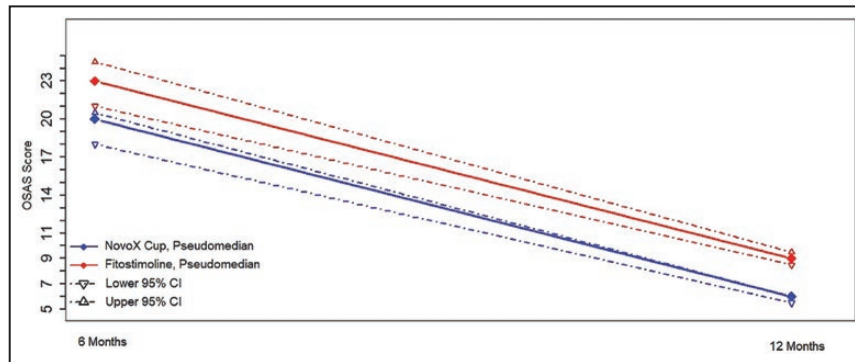


Figure 4. Six and 12 months postoperatively, independent observers scored surgical scars on the OSAS (ie, the observer component of the Patient and Observer Scar Assessment Scale [POSAS]). Observers were blinded to the type of surgical dressing applied. CI, confidence interval.

The short-scar technique has been shown to yield satisfactory results of single-stage augmentation-mastopexy after massive weight loss,³³ and compared with the inverted T maneuver, mastopexy patients rated the short-scar technique as superior with regard to satisfaction with breast appearance.²⁶ However, for women undergoing breast surgery who are not candidates for the short-scar technique,³⁴ treatment with oxygen-enriched oil postoperatively may reduce the number of patients with poor outcomes owing to wound-healing complications. Additionally, a survey completed by nearly 500 members of the American Society for Aesthetic Plastic Surgery indicated that the inverted T incision is the most popular mastopexy technique among surgeons.³⁵ Hence, there remains a need for treatments that support wound healing when the inverted T pattern is employed.

The oxygen-enriched olive oil bra is simple to apply by the patient or the clinician and is painless to remove. By contouring to the breast, the oxygen-enriched olive oil bra maximizes contact between the oxygenated oil and the wound bed, retaining moisture and minimizing open space into which exudate and bacteria could accumulate.¹⁸ Moreover, oxygen-enriched olive oil is not associated with antibiotic resistance, unlike many other topical anti-infective agents³⁶, and it is believed that exerts its biological benefits mainly through its anti-oxidants constituents demonstrating an anti-inflammatory activity and an inhibitory effect on cyclooxygenase enzymes.³⁷

The results of this study suggest that the oxygen-enriched olive oil bra ameliorates postoperative pain, decreases the rate of wound-related complications, and supports wound healing toward the formation of a more aesthetically pleasing scar.

The strengths of this study include its large sample size and the high proportion of patients who presented for

1 year of follow-up. To minimize bias, the study design included blinding of patients and observers to the surgical dressing applied. Baseline patient demographics and rates of reoperation (unrelated to scar quality; oxygen-enriched olive oil bra: 0.8% [1 in 120 patients]; Fitostimoline: 1.7% [2 in 120]; Table 2) were similar in the groups. However, patients were not allocated randomly to each treatment arm. Therefore, we cannot rule out that the study findings were affected by selection bias.³⁸ Moreover, since the control group received Fitostimoline as a comparative dressing, the findings might not be transferable to other types of conventional dressings.

Innovative wound-healing approaches are needed for aesthetic and reconstructive fields alike.³⁹ In the present study, we demonstrate that the treatment of complex surgical wounds of the breast with oxygen-enriched olive oil significantly suppresses pain and yields an improved scar, compared with standard wound dressings. Work is ongoing to assess the utility of the oxygen-enriched olive oil bra in patients undergoing breast surgery for nonaesthetic indications, including mastectomy and reconstruction associated with fungating breast wounds.

CONCLUSIONS

Treatment with oxygen-enriched olive oil supports wound healing in several ways: by maintaining a moist environment, oxygenating tissue, promoting a revascularized granulation bed, stimulating reepithelialization, and curtailing secondary infection.¹⁸ In this study of 240 women who received augmentation-mastopexy and had surgical wounds dressed with either the oxygen-enriched olive oil bra—containing oxygenated olive oil—or a standard medicated gauze, we found that patients treated with the oxygen-enriched olive oil bra

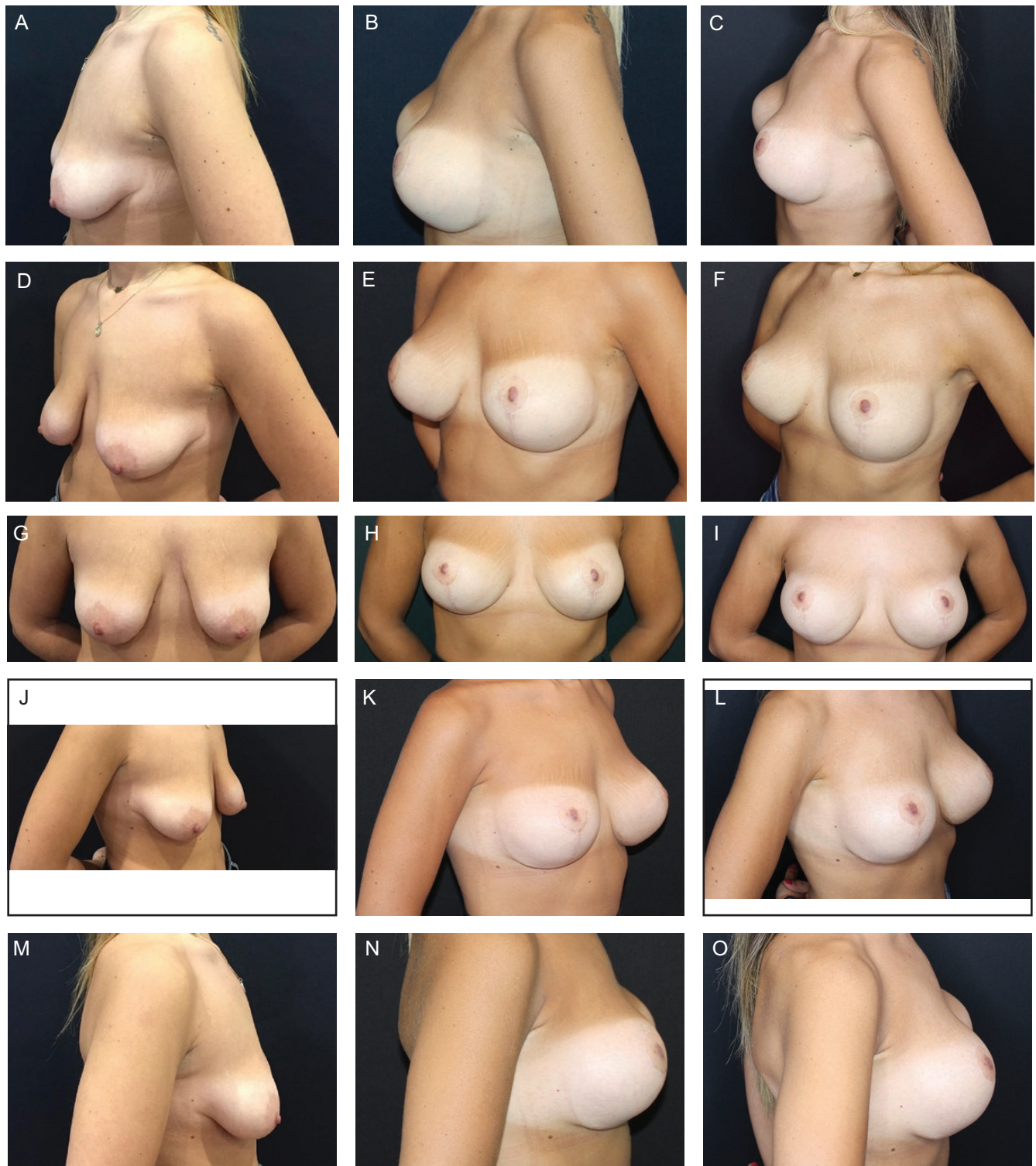

Figure 5. This 27-year-old woman underwent augmentation-mastopexy with the placement of 360-mL implants (A, D, G, J, M). Her surgical wounds were dressed for 2 weeks with the NovoX Cup, which is lined with oxygen-enriched olive oil. (B, E, H, K, N) Six months postoperatively. (C, F, I, L, O) One year postoperatively.

had decreased pain and an improved surgical scar, as scored by the patient and by impartial observers. Our results suggest that the oxygen-enriched olive oil bra

is a safe, effective modality that may help avoid unsatisfactory wound outcomes associated with complex breast surgery.



Figure 6. This 27-year-old woman underwent augmentation-mastopexy with the placement of 505-mL implants (A, D, G, J, M). After surgery, her surgical wounds were dressed with Fitostimoline gauze for 2 weeks. (B, E, H, K, N) Six months postoperatively. (C, F, I, L, O) One year postoperatively.

Supplemental Material

This article contains supplemental material located online at www.asjopenforum.com.

Acknowledgments

Medical writing assistance was provided by ClearView Medical Communications (Wilmington, DE).

Disclosures

The authors declared no potential conflicts of interest with respect to the research, authorship, and publication of this article.

Funding

Moss SpA (Lesa, Novara, Italy) provided financial support for the work conducted to prepare this article but was not involved directly in the preparation of the manuscript or the decision to publish.

REFERENCES

1. Spear S. Augmentation/mastopexy: "surgeon, beware". *Plast Reconstr Surg*. 2003;112(3):905-906.
2. Eisenberg T. Simultaneous augmentation mastopexy: a technique for maximum en bloc skin resection using the inverted-T pattern regardless of implant size, asymmetry, or ptosis. *Aesthetic Plast Surg*. 2012;36(2):349-354.
3. Khavanin N, Jordan SW, Rambachan A, Kim JYS. A systematic review of single-stage augmentation-mastopexy. *Plast Reconstr Surg*. 2014;134(5):922-931.
4. Marlino S, Cagli B, Vitale A, et al. Bleeding in plastic-aesthetic surgery: a prognostic pathway with clinical application. *Aesthetic Plast Surg*. 2020;44(1):201-206.
5. Stevens WG, Stoker DA, Freeman ME, Quardt SM, Hirsch EM, Cohen R. Is one-stage breast augmentation with mastopexy safe and effective? A review of 186 primary cases. *Aesthet Surg J*. 2006;26(6):674-681.
6. Swanson E. Comparison of vertical and inverted-T mammoplasties using photographic measurements. *Plast Reconstr Surg Glob Open*. 2013;1(9):e89.
7. Stevens WG, Macias LH, Spring M, Stoker DA, Chacón CO, Eberlin SA. One-stage augmentation mastopexy: a review of 1192 simultaneous breast augmentation and mastopexy procedures in 615 consecutive patients. *Aesthet Surg J*. 2014;34(5):723-732.
8. Schreml S, Szeimies RM, Prantl L, Karrer S, Landthaler M, Babilas P. Oxygen in acute and chronic wound healing. *Br J Dermatol*. 2010;163(2):257-268.
9. Kimmel HM, Grant A, Ditata J. The presence of oxygen in wound healing. *Wounds*. 2016;28(8):264-270.
10. auf dem Keller U, Kumin A, Braun S, Werner S. Reactive oxygen species and their detoxification in healing skin wounds. *J Investig Dermatol Symp Proc*. 2006;11(1):106-111.
11. Dunnill C, Patton T, Brennan J, et al. Reactive oxygen species (ROS) and wound healing: the functional role of ROS and emerging ROS-modulating technologies for augmentation of the healing process. *Int Wound J*. 2017;14(1):89-96.
12. Valacchi G, Fortino V, Bocci V. The dual action of ozone on the skin. *Br J Dermatol*. 2005;153(6):1096-1100.
13. Bocci V, Valacchi G, Corradeschi F, et al. Studies on the biological effects of ozone: 7. Generation of reactive oxygen species (ROS) after exposure of human blood to ozone. *J Biol Regul Homeost Agents*. 1998;12(3):67-75.
14. Aghaei M, Aghaei S, Sokhanvari F, et al. The therapeutic effect of ozonated olive oil plus glucantime on human cutaneous leishmaniasis. *Iran J Basic Med Sci*. 2019;22(1):25-30.
15. Guinesi AS, Andolfatto C, Bonetti Filho I, Cardoso AA, Passaretti Filho J, Farac RV. Ozonized oils: a qualitative and quantitative analysis. *Braz Dent J*. 2011;22(1):37-40.
16. Sadowska J, Johansson B, Johannessen E, Friman R, Broniarz-Press L, Rosenholm JB. Characterization of ozonated vegetable oils by spectroscopic and chromatographic methods. *Chem Phys Lipids*. 2008;151(2):85-91.
17. Laureti S, Aborajoo E, Mattioli B, Poggioli G. Treatment of minor dehiscence after endorectal advancement flap in perianal Crohn's fistulas with ozonized oil NOVOX®. *Tech Coloproctol*. 2016;20(2):139-140.
18. Giulia V, Teresita G, Umberto C, et al. Reactive oxygen species in an oleic matrix for healing deep and narrow wounds: a case series. *Gastrointest Nurs*. 2020;18(Sup4 European Wound, Ostomy and Continence Supplement):S23-S30.
19. Regnault P. Breast ptosis. Definition and treatment. *Clin Plast Surg*. 1976;3(2):193-203.
20. Chaturvedi A, Meswani R, Shah S, et al. An Indian clinical trial to assess wound healing activity and safety of Fitostimoline® 15%+1% cream as topical treatment of different type of wounds. *J Plast Dermatology*. 2010;6:3.
21. Sanniec K, Adams WP. The tissue-based triad in augmentation mastopexy: single-stage technical refinements. *Aesthet Surg J*. 2019;39(12):1331-1341.
22. Adams WP Jr, Culbertson EJ, Deva AK, et al. Macrot textured breast implants with defined steps to minimize bacterial contamination around the device: experience in 42,000 implants. *Plast Reconstr Surg*. 2017;140(3):427-431.
23. Santorelli A, Rossano F, Cagli B, Avvedimento S, Ghanem A, Marlino S. Standardized practice reduces complications in breast augmentation: results with the first 290 consecutive cases versus non-standardized comparators. *Aesthetic Plast Surg*. 2019;43(2):336-347.
24. Draaijers LJ, Tempelman FR, Botman YA, et al. The patient and observer scar assessment scale: a reliable and feasible tool for scar evaluation. *Plast Reconstr Surg*. 2004;113(7):1960-1965; discussion 1966.
25. Ahad NA, Othman AR, Yahaya SSS. Type I error rates of the two-sample pseudo-median procedure. *J Mod Appl Stat Methods*. 2011;10(2), article 3. doi:10.22237/jmasm/1320120120
26. Pontes GH, Mendes Carneiro Filho FS, Vargas Guerrero LA, Takahashi Rodrigues Pinto C, Serra-Guimarães F. Patient satisfaction following inverted-T and short-scar mammoplasty as

- measured by the Breast Evaluation Questionnaire 55. *Aesthet Surg J*. 2020. doi:10.1093/asj/sjaa236 [Epub ahead of print].
27. Pietrocola G, Ceci M, Preda F, Poggio C, Colombo M. Evaluation of the antibacterial activity of a new ozonized olive oil against oral and periodontal pathogens. *J Clin Exp Dent*. 2018;10(11):e1103-e1108.
 28. Kumar T, Arora N, Puri G, Aravinda K, Dixit A, Jatti D. Efficacy of ozonized olive oil in the management of oral lesions and conditions: a clinical trial. *Contemp Clin Dent*. 2016;7(1):51-54.
 29. Patel PV, Kumar S, Vidya GD, Patel A, Holmes JC, Kumar V. Cytological assessment of healing palatal donor site wounds and grafted gingival wounds after application of ozonated oil: an eighteen-month randomized controlled clinical trial. *Acta Cytol*. 2012;56(3):277-284.
 30. Patel PV, Kumar V, Kumar S, Gd V, Patel A. Therapeutic effect of topical ozonated oil on the epithelial healing of palatal wound sites: a planimetric and cytological study. *J Investig Clin Dent*. 2011;2(4):248-258.
 31. Song M, Zeng Q, Xiang Y, et al. The antibacterial effect of topical ozone on the treatment of MRSA skin infection. *Mol Med Rep*. 2018;17(2):2449-2455.
 32. Akiyo M, Shotaro S, Nariko S, Shigeru S, Toshiaki M. Therapeutic effects of ozonized olive oil in the treatment of intractable fistula and wound after surgical operation. *J Jpn Surg Assoc*. 2000;61(6):1383-1389.
 33. Salgarello M, Visconti G. Short-scar augmentation mastopexy in massive-weight loss patients: four-step surgical principles for reliable and reproducible results. *Aesthetic Plast Surg*. 2020;44(2):272-282.
 34. Nahai F. Scar wars. *Aesthetic Plast Surg*. 2000;24(6):461.
 35. Rohrich RJ, Gosman AA, Brown SA, Reisch J. Mastopexy preferences: a survey of board-certified plastic surgeons. *Plast Reconstr Surg*. 2006;118(7):1631-1638.
 36. Travagli V, Zanardi I, Valacchi G, Bocci V. Ozone and ozonated oils in skin diseases: a review. *Mediators Inflamm*. 2010;2010:610418.
 37. Beauchamp GK, Keast RS, Morel D, et al. Phytochemistry: ibuprofen-like activity in extra-virgin olive oil. *Nature*. 2005;437(7055):45-46.
 38. Pannucci CJ, Wilkins EG. Identifying and avoiding bias in research. *Plast Reconstr Surg*. 2010;126(2):619-625.
 39. Öhnstedt E, Lofton Tomenius H, Vågesjö E, Phillipson M. The discovery and development of topical medicines for wound healing. *Expert Opin Drug Discov*. 2019;14(5):485-497.